



Crohn's Disease (CD)

Pathophysiology

Ulcerative Colitis (UC)

In children, CD is **more common** than UC. Inflammation in CD is usually **transmural** and can affect any part of the GI tract ("gum to bum")

Inflammation in UC **only affects the intestinal mucosa** of the **colon**. Etiology is a combination of genes, environment, and gut microbiota dysbiosis

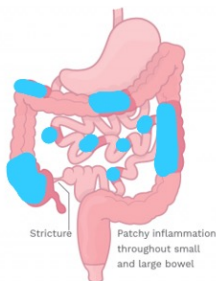
Presentation

Abdominal pain, bloody diarrhea, weight loss

Diarrhea, hematochezia, abdominal pain

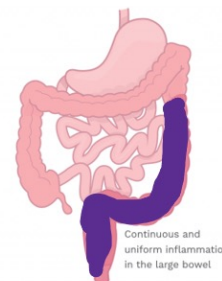
Can also have RLQ pain (terminal ileitis), **perianal** disease, growth retardation, delayed puberty, short stature, nausea or vomiting, and fatigue

Can also have tenesmus, urgency. May have acute weight loss



Extra-intestinal manifestations

Seen in both CD and UC! Erythema nodosum (tender erythematous nodules usually on the shins), pyoderma gangrenosum (small, red nodules that erode into painful ulcerations), oral ulcers, arthralgias, arthritis. Primary sclerosing cholangitis (PSC) can happen in CD or UC, as well as autoimmune hepatitis.



Lab Tests

CBC → anemia

ESR, CRP → may be elevated

Hypoalbuminemia

AST, ALP, GGT → can be abnormal

Fecal Calprotectin → elevated

Stool Cultures (to exclude infection)

Investigations

- Both **gastroscopy and colonoscopy** performed (since CD can be anywhere gum to bum).
- MR enterography helps assess severity and distribution.

Differential diagnosis

- Gastroenteritis
- Malabsorption syndromes
- Celiac disease
- Irritable bowel syndrome (IBS)

MANAGEMENT

CD:

Goal is to achieve remission and promote mucosal healing.

UC

Induction: EEN (exclusive enteral nutrition) or corticosteroids.

Acute flares: 5-Aminosalicylates and corticosteroids.

Maintenance: immunosuppression via methotrexate, azathioprine, or biologics. Surgery is not a curative treatment modality.

Maintenance: immunosuppressive (sulfasalazine, azathioprine, biologics). May be surgically resectable.

Toxic megacolon can be a complication!! Dx made with AXR/CT. Fluids, anti-inflammatories, and antibiotics for treatment. May need surgery if no improvement on meds.

Published December, 2021

Prachi Shah (MD Student C2023, University of Alberta), Dr. Matthew Carrol (Pediatric Gastroenterologist, Stollery Children's Hospital), for www.pedscases.com